



## THE EFFECTIVENESS OF MORINGA OLEIFERA SEED OIL AS AN ANTIOXIDANT

**1Assistant Lecturer. Saad Farhan Bunyan**

The General Directorate of Education in Maysan Governorate - Iraq

Gmail: saadfarhan69@yahoo.com

**2Assistant Lecturer. Huda Adel Ruhoma**

The General Directorate of Education in Maysan Governorate - Iraq

Gmail: hassamiraqi@gmail.com

Article history:	Abstract:
<p><b>Received:</b> 6<sup>th</sup> August 2023 <b>Accepted:</b> 6<sup>th</sup> September 2023 <b>Published:</b> 6<sup>th</sup> October 2023</p>	<p>The research was conducted to study the extent of the preventive and therapeutic role of raw moringa seed oil against cadmium toxicity that affects the functions and organs of people who are exposed to continuous and direct doses as a result of their occupation in dealing industries. With cadmium as a raw material, it is also used in the manufacture of fertilizers, as well as inhibitory concentrations and doses.</p> <p>For Moringa oleifera oil for oxidative stress resulting from the toxic dose of cadmium, the mice were divided into four groups, each group consisting of five adult mice. The first control and comparison group was injected with a saline solution (0.9) sodium chloride, and the second group was treated with (MSO). Oral route at a dose of (1 ml/kg) for 21 days, and the third group was treated with (cadmium) with a cadmium chloride compound in saline solution at a dose of (2 ml/kg).</p> <p>The fourth group was first given a single dose of cadmium chloride (2 mg kg), then (MSO) after seven days of treatment with cadmium chloride, and there were highly significant changes in the levels of ALT, AST, ALP, MD, total protein, urea, creatine, and catalase. . (<math>p&gt;0.05</math>) in the group that was dosed with cadmium chloride compared to the control group, but their levels returned to normal when the group was treated with Moringa oleifera seed oil. It is concluded from this study that Moringa oleifera seed oil has a protective and effective effect. Therapeutic effect on kidney and liver indicators by chelating free radicals generated by cadmium toxicity. Similar studies have indicated.</p>

**Keywords:** Effect of selenium , moringa oleifera seed oil , oxidative stress , kidney diseases.

### INTRODUCTION:

Many causes of pathological problems are related to the effect of free radicals and their role in the complications of the disease, resulting in a disturbance between the concentration of active oxygen species and antioxidants present in the body. This leads to an increase in the formation of free radicals that produce over-oxidation of fats, leading to breakdown of polyunsaturated fatty acids and tissues damage ( 1 ).

Cadmium is a heavy metal, a dangerous industrial and environmental pollutant. It is present in the surrounding environment of humans such as water, air, and soil. Highest cadmium concentration is mainly found in kidney, heart and liver (1).

Cadmium is also used in some local industries such as the manufacture of batteries and fertilizers. Cigarette smoking is an important source for the production of this element, and its concentration in the air ranges from 0.1-0.5 1-2 and (15-190) nanograms / M3 in rural and urban areas.

The presence of cadmium in the environment causes many metabolic and tissue changes, resulting changes in gene expression and programmed cell death. This is due to its ability to form active oxygen compounds, which include hydrogen peroxide and hydroxide ions, which affect all cells of the body.(2)

The study conducted by( Whelton and his group) indicated that administering low concentration of cadmium (20) ppm orally ) to some farm animals leads to its concentration in the kidneys twice as high as its concentration in the liver, while injecting it in a higher dose (higher than 0.5) mg / kg or higher than (50) parts per million,) its concentration increases in the liver. People working in the field of industries that use cadmium as a basis for manufacturing and are exposed to it daily are at a high risk , an increase in acute and chronic concentrations of this element affects their organs and lipid metabolism physiologically (3) .

Moringa Oleifera Tree: Moringa Oleifera and its antioxidant activity .

They are a rich source of vitamins and amino acids and contain carotenoids (found in vegetables, fruits , organic compounds, pigments, isothiocyanates, niacin and gels. Cosinols, minerals, and sterols are all powerful constituents of antioxidants(4).

Moringa is one of the most important herbs with effective properties in inhibiting the production of free radicals, reducing the intensity of lipid peroxidation, and increasing the activity of antioxidant enzymes. One way to prevent oxygen-containing free radicals is to eat food that contains antioxidants. In recent years, the incidence of disease has decreased with the increase in consumption of foods rich in antioxidants.( 5).

#### **MATERIALS AND METHODS:**

The experiment was conducted for a month, where the animals were placed in special iron cages. The animals were divided into four groups, each group consisting of 5 rats, where all logistical matters were prepared and unified laboratory conditions in terms of food, water and temperature ranging between ( $2 \pm 25$ ) C, ventilation and lighting (14) hours of light (10) hours of darkness. Its weight was taken for comparison, which ranged between ( $150 \pm 10$ ) kilograms.

The rats were distributed randomly into the four groups, taking into account the body weight, and left seven days to acclimatize to the place. as follows.

The first group (the control group) was treated with physiological saline at a dose of (0.9%) NaCl. For the purpose of living in the same atmosphere as the rest of the groups, they were given doses of water and food throughout the experiment period.

The second group (moringa oleifera seed oil group) This group took moringa oleifera seed oil orally at a dose of (1 ml / kg) of body weight for a period of 30 days .

The third group was treated with (cadmium chloride compound) in saline by peritoneal injection at a dose of (2 ml / kg) of body weight .

The fourth group (cadmium chloride and MSO) was injected intraperitoneally with a compound of cadmium chloride in saline at a dose of (2 ml / kg), same as the case with the third group, and then treated with MSO (1 ml / kg) orally after a week of treatment with cadmium chloride .

The rats were weighed, dissected, and blood samples were taken to conduct measurements. Moreover biochemical indicators, plasma, rat tissues, and kidney function examination were done to evaluate the percentage of oxidation markers in the kidney

(malondialdehyde, glutathione peroxidase, and superoxide dismutase). After that the results were collected, analyzed, and discussed.

The following statistical program were used :

(Statistical Analysis System Version\spss21) The averages were compared using the least significant difference ( $0.05 > p$ ) ( 11).

#### **RESULTS AND DISCUSSION:**

•The results showed a decrease in body weight after 10 days of giving cadmium chloride due to lack of food intake. As for the weight of both the liver and kidneys, it was found that there was a slight decrease in their weights.

The group treated with Moringa oleifera oil led to an increase in body weight, especially in the fourth group, and this is an indication of elimination Of the toxic effects of cadmium.

Blood is a very important criterion for knowing a person's state of health. Blood tests confirm anemia due to cadmium poisoning, which leads to a disturbance in the work of the enzymes that make up hemoglobin in the blood..

With regard to the number of blood cells, a decrease was found in the number of red blood cells, hemoglobin levels and hematocrit in the blood as a result of treatment with cadmium chloride compared with the control group. As for white blood cells, a decrease in the total number was observed.

It was also found an increase in the percentage of neutral neutrophils and mononuclear leukocytes, while the lymphocytes were decreased and no change observed in the basophils as a result of exposure to cadmium.

Results of analyzes in the levels of MCH, MCV, MCHC). The noticeable change in the blood content is due to the process of oxidative stress, i.e. the presence of fat oxidation in the membranes of red blood cells and the occurrence of oxidation of hemoglobin and thus the lack of survival of blood cells, (and the reason for the resulting ) A decrease in white blood cells is the due to a collapse of the body's immune system as a result of the poisoning dose, while the amount of improvement in blood measurements of the fourth group was proven. The ability of vitamin C in Moringa oleifera seed oil (to chelate free radicals) and thus get rid of oxidative stress (14).

Mackova and his group when exposed to it, especially on the process of producing red blood cells and hemoglobin, as it affected the size and shape of those cells, and this is what (14).

Referred to the study of (13) also proved that, and the results are consistent with what was reached by (Morgan and his group), as well as Yammano and his group

With regard to biochemical measurements

Cadmium has an effect on the biochemical variables on the tissues of the organs of the body, especially in the liver and kidneys. ((When injected into mice, its concentration begins to decline and reaches (1%) and even less than that after 24 hours. It binds initially to albumin and then binds to a protein similar in molecular weight to metallothionein and then It unites with hemoglobin in red blood cells and the blood is distributed to the organs.

Cadmium chloride injection caused impairment in renal function and an increased activity of serum transaminase, alanine and alkaline phosphatase enzymes (ALT, AST, AIP) and impaired renal function through urea levels

Chronic exposure to cadmium damages the kidneys. It structurally and functionally affects the proximal and rectal tubules and glomeruli of the renal unit, resulting in the deposition of uric acid in the joints and kidneys, resulting in increased excretion in the kidneys. Blood: After treatment for days, serum levels of bilirubin, lactate dehydrogenase and glutamate transpeptidase increased as a result of injection of cadmium chloride compounds compared to the control group and the group given (MSO) (4).

A clear sign of oxidative stress and the elevated levels of thiobarbituric acid (TBARS) was observed in the kidneys compared to the control group and the vitamin C-treated group. The levels of fatty sulfur in liver and kidney tissues are evidence of oxidative stress. Histological changes occurred as a result of enzyme changes. Catalase, glutathione reductase, glutathione peroxidase, glutathione S-transferase activity, and cardiac glutathione levels were reduced. Treatment with vitamin (C), which is found in high concentrations in Moringa oleifera seed oil, led to an improvement in the biochemical and histological levels that appeared in the histological analysis .

With regard to liver and kidney tissues, this study went to prove the severity of oxidative stress due to acute and chronic exposure to cadmium, which damages cell walls, increased lipid oxidation indicators, and increases thiobarbituric acid. Cadmium toxicity, which is directly and indirectly exposed to living organisms. Many studies have shown that adding ascorbic acid to the diets of some birds works to improve the characteristics of their semen and increase its immunity against diseases through resistance to free radicals(15)

**RECOMMENDATIONS:**

1 -Workers in laboratories, factory owners, and artisans who practice crafts through which they are directly exposed to the dangerous cadmium element, directing them to the need to beware of the sources of this environmental pollutant, because it has a significant impact on the increase in the rates of blood, liver, and kidney diseases. directly with this toxic element.

2- Recommending that Moringa oleifera seed oil be an important ingredient for use in cases of exposure to cadmium toxins because of its role in mitigating those toxic effects, and continuing work to conduct extensive studies to reach the optimal therapeutic dose that ends these toxic effects of cadmium

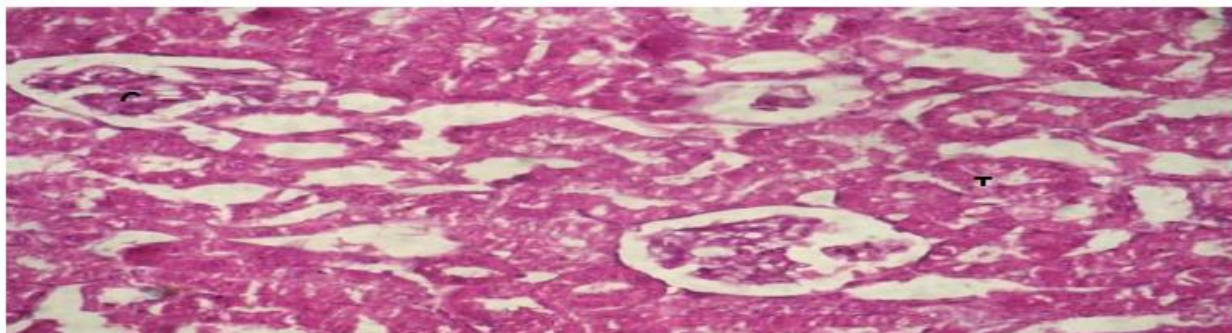


Figure1

Microscopic examination of the kidney of control groups reveals normal kidney tubules, glomeruli showing normal thickness in Basement membrane, no epithelial

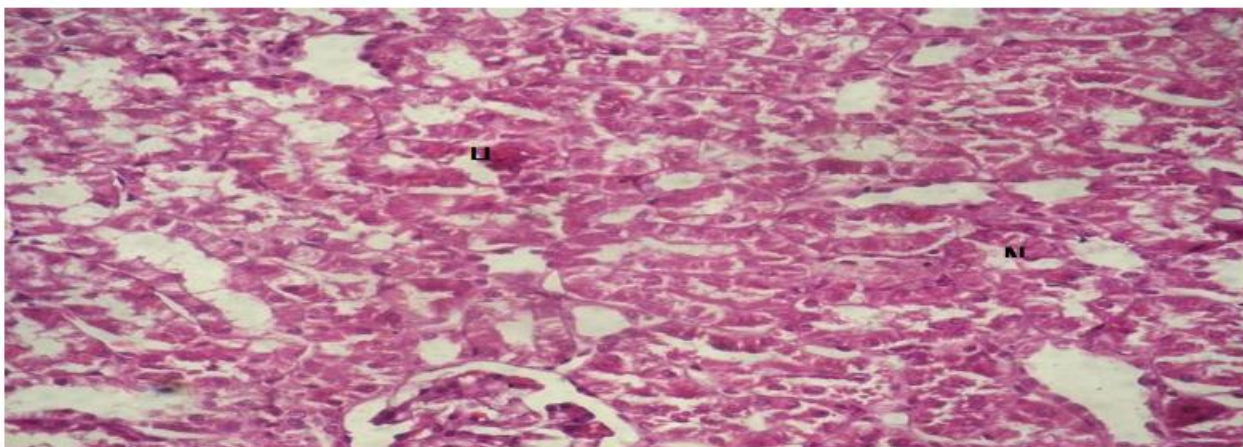
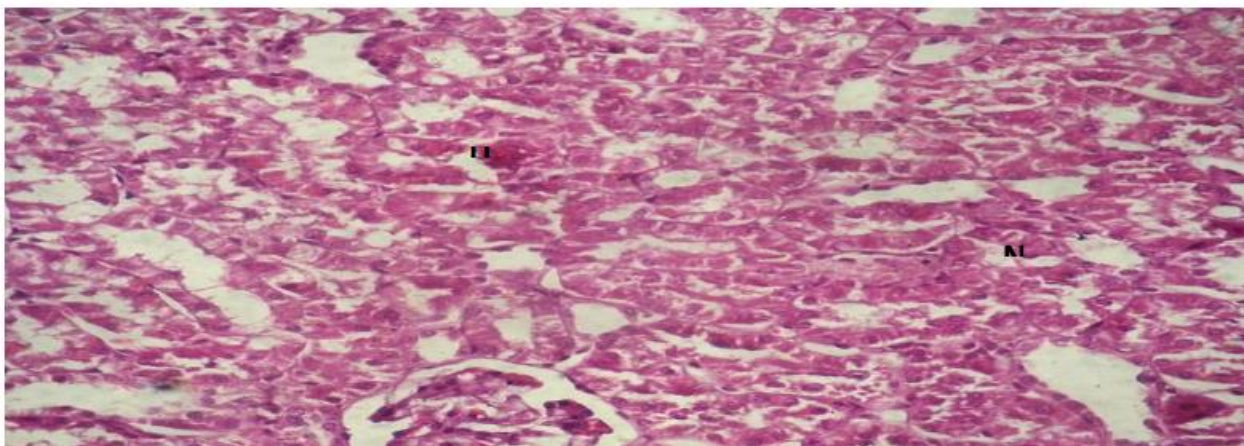
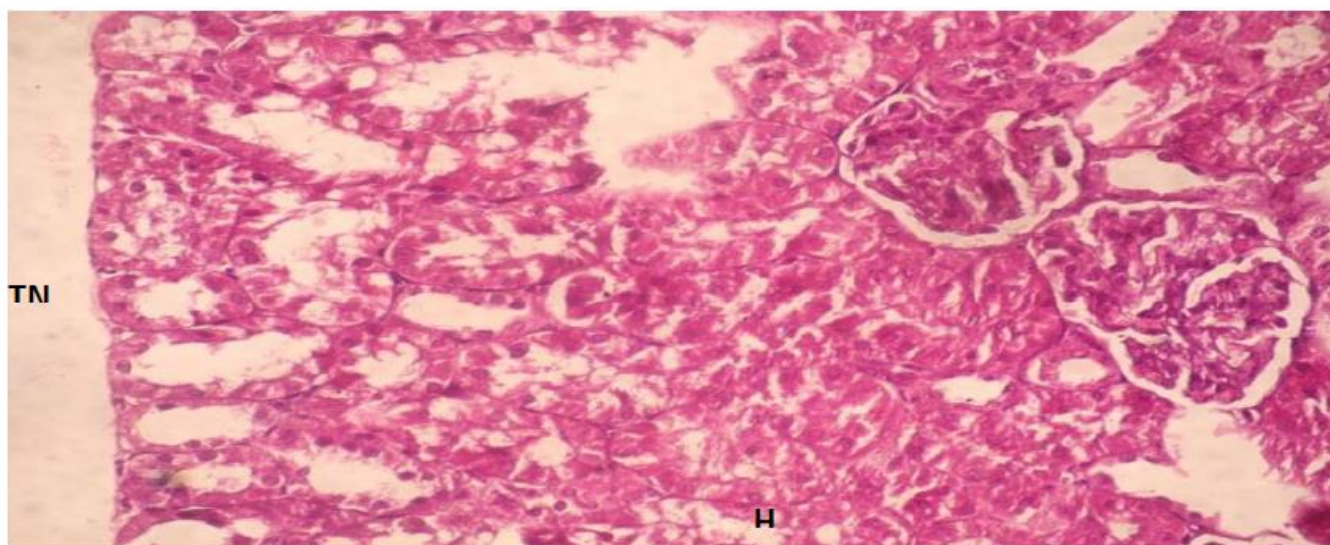


Figure 2:

Microscopic examination of the kidney the moringa group reveals normal kidney smooth muscle fibers showing no degeneration, no infraction, no inflammation



**Figure3 :** Microscopic examination of the kidney – cadmium chloride group reveals hydropic change in tubules (H), necrosis in renal tubular cells (N).



**Figure4:** Microscopic examination of the kidney – Moringa+ cadmium chloride group reveals mild in hydropic change (H) was still these is necrosis in renal tubular cells (TN).

**Table 1-Serum urea (mmol/l) of rat treated with *Moringa* seeds oil (MSO) and Cd**

Group	Control	MSO	Cd	MSO + Cd
Sum	35.67	33.66	55.11	38.77
Mean	7.211	6.654	10.877	8.098
St Div	0.431	0.487	0.914	0.332
St Error	0.365	0.423	0.819	0.301
	C	C	Abd	C

**Table 2- Serum creatinine (mg/dl) of rat treated with *Moringa* seeds oil (MSO) and Cd**

Group	Control	MSO	Cd	MSO + Cd
Sum	2.750	2.21	4.02	2.52
Mean	0.541	0.442	0.718	0.509
St Div	0.0349	0.0421	0.088	0.058
St Error	0.033	0.0380	0.087	0.03
	C	C	Abd	C

**Table 3- Kidney TBARS (nmol MDA/mg protein) of rat treated with *Moringa* seeds oil (MSO) and Cd**

Group	Control	MSO	Cd	MSO + Cd
Sum	154.596	158.808	248.04	192.192
Mean	30.919	31.762	49.608	38.438
St Div	7.509	7.949	7.731	1.453
St Error	6.716	7.110	6.914	1.299
	Cd	Cd	Abd	Abc

**Table 4 - Kidney catalase (µmoles of H<sub>2</sub>O<sub>2</sub> consumed/min/mg protein) of rat treated with moringa seed oil (MSO) and Cd**

Group	Control	MSO	Cd	MSO + Cd
Sum	112.881	118.934	89.944	102.315
Mean	22.576	23.787	17.989	20.463
St Div	1.059	0.908	0.955	0.301
St Error	0.947	0.812	0.854	0.268
	Cd	Acd	Abd	abc

**Table 5- Kidney GSH (nmol/mg protein) of rat treated with moringa seed oil (MSO) and Cd**

Group	Control	MSO	AFB <sub>1</sub>	MSO+AFB <sub>1</sub>
Sum	637.08	655.98	404.04	495.06
Mean	127.416	131.196	80.808	99.012
St Div	5.139	11.391	8.944	5.049
St Error	4.597	10.188	8.00	4.516
	Cd	Cd	Abd	abc

**Table 6 - Kidney glutathione peroxidase (GPX) µg of glutathione utilized/min/mg protein) of rat treated with moringa seed oil (MSO) and Cd**

Group	Control	MSO	AFB <sub>1</sub>	MSO+AFB <sub>1</sub>
Sum	24.5581	26.26	12.888	19.695
Mean	4.912	5.252	2.578	3.939
St Div	0.434	0.195	0.326	0.592
St Error	0.388	0.175	0.292	0.529
	Cd	Cd	Abd	Abc

**Table 7 - Kidney glutathione reductase (GR) (nmoles of GSSG reduced/min/mg protein) of rat treated with moringa seed oil (MSO) and Cd**

Group	Control	MSO	AFB <sub>1</sub>	MSO + AFB <sub>1</sub>
Sum	21.627	21.705	10.047	15.731
Mean	4.326	4.341	2.010	3.146
St Div	0.363	0.344	0.4019	0.340
St rror	0.325	0.307	0.359	0.304
	Cd	Cd	Abd	abc

**Table 8 - Kidney glutathione S-transferase (GST) (ηmol CDNB conjugate formed/min/mg protein) of rat treated with moringa seed oil (MSO) and (Cd )**

Group	Control	MSO	Cd	MSO + Cd
Sum	1543.505	1588.777	1000.508	1314.326
Mean	308.701	317.755	200.102	262.865
St Div	18.946	19.3015	11.644	30.062
St Error	16.946	17.264	10.415	26.888
	Cd	Cd	Abd	abc

**LIST OF ABBREVIATION**

- ALP: alkaline phosphatase
- ALT – alanine aminotransferase,
- AST – aspartate aminotransferase,
- CAT – catalase
- LDH: lactate dehydrogenase
- MCH: mean corpuscular hemoglobin
- MCHC: mean corpuscular hemoglobin concentration
- MCV: mean cell volume
- GPx: glutathione peroxidase
- GR: glutathione reductase
- GSH – reduced glutathione
- GST: glutathione-S-transferase
- Hb: hemoglobin
- HCC: hepatocellular carcinoma
- HCT: hematocrit
- HDL – high density lipoproteins
- HK: hexokinase
- TBARS– thiobarbituric acid reactive substances
- WBC: white blood cell

**LIST OF FIGURES**

- Fig (1)** Microscopic examination of the kidney of control groups reveals normal kidney tubules, glomeruli showing normal thickness in Basement membrane, no epithelial.
- Fig (2)** Microscopic examination of the kidney the moringa group reveals normal kidney smooth muscle fibers showing no degeneration, no infraction, no inflammation.
- Fig(3)** Microscopic examination of the kidney – cadmium chloride group reveals hydropic change in tubules (H), necrosis in renal tubular cells (N).
- Fig(4)** Microscopic examination of the kidney – Moringa+ cadmium chloride group reveals mild in hydropic change (H) was still these is necrosis in renal tubular cells (TN).

**REFERENCES:**

1. Janker, Mona Hussein, (2005) Environmental effects of cadmium .
2. Afifi, Fathi Abdel Aziz (2000). The course of environmental toxins and pollutants in the components of the ecosystem, Dar Al-Fajr for Publishing and Distribution, Cairo. Egypt
3. Janker, Mona Hussein and Taha, Intisar Ghanem, (2006). Study of the effect of lead on some aspects of life of male Swiss white mice.
4. Hassan, Ashwaq Ahmed, (2006) The effect of antioxidants on some physiological a biochemical aspects of cadmium-treated female rats during pregnancy and lactation PhD thesis, College of Veterinary Medicine, University of Mosu
5. Yassin, Abd al-Rahman Salem, (2000) The effect of cadmium on some components of blood and tissues in male rabbits. Master's thesis, College of Education, University of Mosul
6. Al-Omar, Muthanna Abdul-Razzaq, (2000) Environmental Pollution, Dar Al-Awael Press for Printing and Publishing, Ammar, Jordan
7. Mahdi Saleh Yassin, Effect of some heavy metals on some aspects of life of the big-mouthed brown fish, PhD thesis, College of Science, University of Mosul,1992
8. Barkeel p. Firas Pro, p. (2011) The role of cadmium in activating cancerous diseases. Damascus University Journal of Health Sciences, Volume 27
9. Jassim Muhammad Jandal.(1971) Folk Medicine. Journal of Dar Al-Kutub Al-Ilmia, Lebanon
10. Essam Mohamed Abdel Moneim, Ahmed bin Ibrahim Al-Turki (2012) Heavy metals, their sources and damage to the environment

11. Arab Labor Organization Arab Institute for Occupational Health and Safety. (2010) Occupational poisoning caused by cadmium and its compounds
12. Janker, Mona Hussein. (2009) Study of the effect of cadmium on some blood components and biochemical variables for male Swiss white mice, PhD thesis, University of Mosul
13. Baeshen. Nabih Abdel Rahman, Saber. Jamal Saber Muhammad, Single and combined genotoxicity test for cadmium and carbofuran in the meristem islet cells of the faba bean plant
14. Mahdi Saleh Yassin, Effect of some heavy metals on some biological aspects of the bigmouthed brown fish, PhD thesis, College of Science, University of Mosul, 1992
15. Janker, Mona Hussein, Shafer, Waad Sabri, (2007) Effect of cadmium on some blood components and its bioaccumulation in tissues and organs of Swiss white male mice
16. Janabi. Adnan Saleh and his group. Maysan Journal of Academic Studies, Issue 14, Volume VII and 2009)
17. Ghazi.Haidar and his group. Maysan Journal of Academic Studies. 2006, No. 10, Volume5.
18. klos, A. (2001). Lead, Cadmium and Mercury content in meals planned for consumption in selected kingdegratens in war saw .IV International Scientific-Technical conference war saw.4-5x.